

## In-vitro and in-vivo Anticoccidial Activities of Berberine against Murine *Eimeria papillata* Infection

Nour E. Sherif<sup>1</sup>, Mahmoud S. Metwaly<sup>1,2</sup>,  
Saleh Al-Quraishy<sup>2</sup> and Mohamed A. Dkhil<sup>2,3\*</sup>

<sup>1</sup>Department of Zoology, Faculty of Science, Suez Canal University, Ismailia, Egypt.

<sup>2</sup>Department of Zoology, College of Science, King Saud University, Riyadh, Saudi Arabia.

<sup>3</sup>Department of Zoology and Entomology, Faculty of Science, Helwan University, Cairo, Egypt.

(Received: 15 March 2014; accepted: 14 May 2014)

Intestinal Eimerian infections are considered to be one of the most highly distributed protozoan parasitic infections among farms and domestic animals, and cause huge economic losses in the field of animal farming and meat production. All recent trends to fight infectious diseases depend upon using treatment of natural origins instead of synthetic drug therapy. Berberine is a plant derived isoquinoline alkaloid with wide spectrum pharmacological and antimicrobial activities. The current study was designed to elucidate the *in-vitro* and *in-vivo* anticoccidial activities of berberine chloride against murine intestinal *Eimeria papillata* infection. *In-vitro* measurements showed that berberine could significantly reduce the viability and sporulation percent of *E. papillata* unsporulated oocyst. In addition, berberine showed a pronounced *in-vivo* anticoccidial activity as revealed by reducing the number of zygotes and developing oocysts within intestinal villi by about 90% and that of schizonts and gamonts by 58% and 30% respectively. Moreover, berberine treatment of *E. papillata* infected mice showed a great increase in the total antioxidant capacity within jejunum tissue. Finally, the results of the study proved both *in-vitro* and *in-vivo* anticoccidial activities of berberine chloride against the murine intestinal *E. papillata* infection, and could effectively correct the induced disruption in the antioxidant capacity within jejunum tissue by such infection.

**Key word:** *Eimeria papillata*, berberine, anticoccidial, *in-vitro*, *in-vivo*.

Coccidiosis is a cosmopolitan disease caused by the protozoan parasite of the genus *Eimeria*, and is considered to be the most important parasitic disease of veterinary importance throughout the world. It affects animal health and production and induces huge economic losses in the field of animal farming, milk and meat production<sup>1</sup>. The infection with Eimerian parasites greatly affect growth and food metabolism and cause loss of animal communities<sup>2,3</sup> and is

characterized by weight depression, severe diarrhea, mucoid and bloody stool and leads finally to dehydration<sup>4,5,6</sup>. Such signs are accompanied by damaged intestinal wall which in turn leads to disturbance in food digestion, absorption and metabolism<sup>7,8</sup>.

Natural products have been used for dietary therapy for several millennia, and some of them allegedly exhibit significant antioxidant activity. Recent studies have showed that a number of plant products, including polyphenols and flavonoids and various plant extracts, exerted an antioxidant action<sup>9</sup>.

Berberine is an isoquinoline alkaloid, present in roots and stem-bark of clinically important medicinal plants<sup>9</sup>. Berberine based formulations, are widely used in traditional systems

\* To whom all correspondence should be addressed.  
Tel.: 00966-14675754; Fax: 00966-14678514;  
E-mail: mohameddkhil@yahoo.com

of medicine<sup>10</sup>. It has demonstrated wide range of pharmacological activities and is not considered to be toxic at doses used in clinical situations, nor has it been shown to be cytotoxic or mutagenic<sup>11</sup>. The current study aims to test the role of berberine as an anticoccidial drug using both invitro and invivo measurements.

## MATERIALS AND METHODS

### In-vitro anticoccidial activities of berberine

A self-healing strain of *E. papillata* was kindly provided by Prof. Mehlhorn (Heinrich Heine University, Duesseldorf, Germany). Several passage processes of *E. papillata* were performed in laboratory mice, followed by oocyst collection from faeces by concentration using floatation technique. Oocysts then were washed several times and suspended in normal saline solution. Using small petri dishes, oocysts were divided into six plates. Three plates were mixed with 0.5% berberine chloride solution and served as BBR-treated oocysts. The other plates were mixed with normal saline and served as control untreated oocysts. Both groups were incubated at 37° C overnight.

Small volumes from all plates were mixed with trypan blue stain for five min and examined under microscope for viability of both control untreated and BBR-treated oocysts. Remaining parts of oocysts were concentrated by centrifugation and mixed with 2.5% potassium dichromate solution and allowed for sporulation process. After six days, the percentage of sporulated oocysts was calculated in both groups.

### In-vivo anticoccidial activities of berberine

Freshly prepared sporulated oocysts of *E. papillata* were washed several times with sterile saline and then surface-sterilized with sodium hypochlorite, and washed at least four times with sterile saline before oral inoculation as described by Schito and Barta (1997)<sup>12</sup>. These oocysts were used to inoculate mice by oral gavaging each mouse with  $1.5 \times 10^3$  sporulated oocysts of *E. papillata* suspended in 100 µl sterile saline.

Berberine chloride was purchased from Sigma Company (St Louis, MO, USA). Each mouse was orally inoculated with 10 mg/Kg berberine chloride. The used dose is in agreement with previous studies on other intestinal protozoan

infections and toxicity measurements<sup>13,14</sup>.

Male Swiss albino mice (9-11 weeks) randomly divided into three groups. The first group received saline and served as control uninfected animals. The second and third groups were orally infected with  $1.5 \times 10^3$  sporulated *E. papillata* oocysts. The 3<sup>rd</sup> group was treated with a daily dose of berberine chloride for five successive days. The experiments were approved by state authorities and followed Saudi Arabian rules for animal protection. Weight change of mice was recorded during the experimental time and at the end of the experiment.

On day 5 *p.i.*, all animals were killed by cervical dislocation and dissected. Pieces of jejunum were freshly prepared, fixed in 10% neutral buffered formalin, and then embedded in paraffin. Sections were cut and stained with hematoxylin and eosin. Number of individual parasitic stages of zygotes and developing oocysts, schizonts and gamonts were determined within ten intestinal crypt villi.

Jejunal homogenate was assayed for total antioxidant capacity using a colorimetric method based on the activity of total antioxidants within jejunum tissue to certain amounts of exogenously added H<sub>2</sub>O<sub>2</sub>. Residual amounts of H<sub>2</sub>O<sub>2</sub> are enzymatically determined yielding colored products<sup>15</sup>.

### Statistical analysis

One-way ANOVA was carried out, and the statistical comparisons among the groups were performed with Duncan's t-test using a statistical package program (SPSS version 17.0). P values are d" 0.05 was considered as significant for all statistical analysis in this study.

## RESULTS AND DISCUSSION

Berberine showed an in-vivo anticoccidial activity against unsporulated *E. papillata* oocysts. Trypan blue stained oocysts (Fig 1) showed a decrease in the number of viable *E. papillata* unsporulated oocysts after berberine incubation. In addition, upon berberine incubation with unsporulated oocysts leads to decreasing the percentage of sporulated oocysts from  $94 \pm 2$  to  $68 \pm 8\%$  after incubation with potassium dichromate solution for six days (Fig 2).

Evaluating individual stage score of *E.*

**Table 1.** Berberine induced alterations in the number of developmental stages per ten VCU of *E. papillata* on day 5 *p.i*

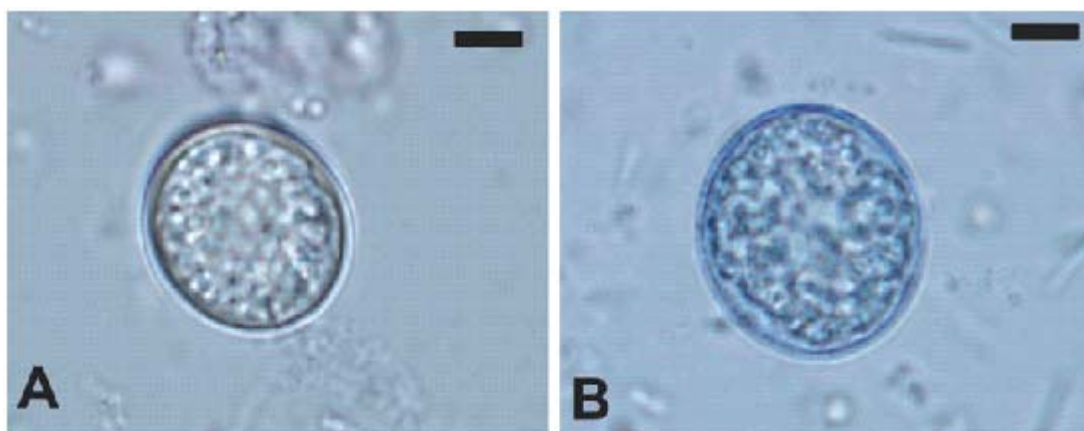
	Oocyst & Zygote	Schizonts	Gamonts
Un-infected (- Berberine)	0±0	0±0	0±0
Infected (- Berberine)	25.3±3.7	37.3±5.2	26.7±2.8
Infected (+Berberine)	2.6±0.5*	15.9±3.2*	19 ±2.7*

Values are Means ± SD. \*P ≤ 0.05 significance for - Berberine vs. +Berberine

*papillata* infected jejunum tissue and after berberine treatment of infected mice showed that upon berberine treatment the number of intracellular schizonts per ten villous crypt unit (VCU) was decreased from 37.3 to 15.9 stage/10 VCU, and that of zygots and developing oocysts was decreased from 25.3 to 2.6. In addition, the number of intracellular gamont stages was decreased from 26.7±2.8 to 19±2.7 stage/ 10 VCU upon berberine treatment of *E. papillata*-infected mice (Table 1, Fig 3).

Previous studies proved the strong activity of berberine salt, extract, or derivatives against other genera of intestinal protozoan infections. It had an *in-vitro* inhibition of the growth of *Giardia lamblia*, *Entamoeba histolytica* and *Trichomonas vaginalis*<sup>16</sup>. All parasites exhibited morphological changes after exposure to berberine sulfate<sup>16</sup>. Berberine also had an *in vivo* and *in vitro* amoebicidal effect on *E. histolytica* and causes degeneration and lysis of the trophozoite forms<sup>17</sup>. It inhibited the growth of *Trichomonas vaginalis* via the formation of large autophagic vacuoles that result in lysis of the trophozoite forms<sup>16</sup>. In addition, berberine has an

*in-vitro* and *in-vivo* anti-protozoan activity against blood parasites as *Leishmania*, *Malaria* and *Trypanosoma*<sup>18</sup>. It also exerts anti-leishmanial effects via inhibition of multiplication, respiration, and macromolecular biosynthesis of amastigote forms of the parasite, interfered with the nuclear DNA of the promastigote form, and inhibited organism maturation<sup>19</sup>. BBR was found to have strong anti-malarian activities<sup>20,21</sup>. It has a high clearance rate of asexual parasitemia<sup>22</sup>. It inhibits telomerase activity of *P. falciparum* in a dose dependent manner<sup>23</sup>. It interacts with plasmodium DNA effectively<sup>24</sup>. Moreover, administration of berberine showed a significant prolongation of the lives of rats infected with *Trypanosoma equiperdum*<sup>25</sup>. Berberine was found to induce programmed cell death in blood stream forms of Trypanosomes (*Trypanosoma brucei*). It exerts its action via DNA intercalation, protein biosynthesis inhibition and cellular cytotoxicity of parasitic forms<sup>25</sup>. In addition, it was found that berberine and its derivatives have cytotoxic activities against *Toxoplasma gondii* parasite and inhibits the growth and replication of tachyzoite forms of the parasite<sup>26</sup>.

**Fig. 1.** Control (A) and trypan blue (B) stained unsporulated *Eimeria papillata* oocysts. Scale bar = 25 µm

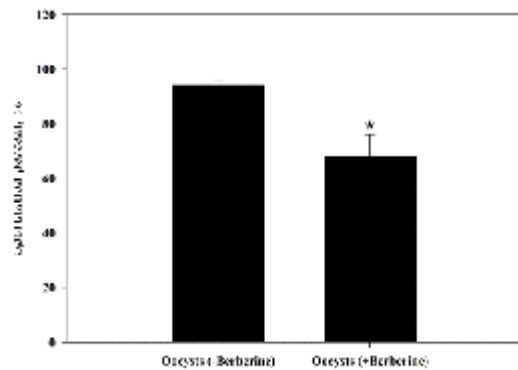


Fig 2. Berberine induced alterations in the percentage of sporulation of unsporulated *Eimeria papillata* oocysts. Values are Means  $\pm$  SD. \* $P \leq 0.05$  significance for "Berberine vs. +Berberine. N=3

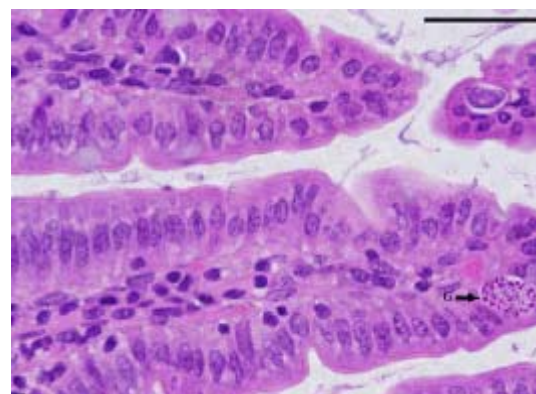
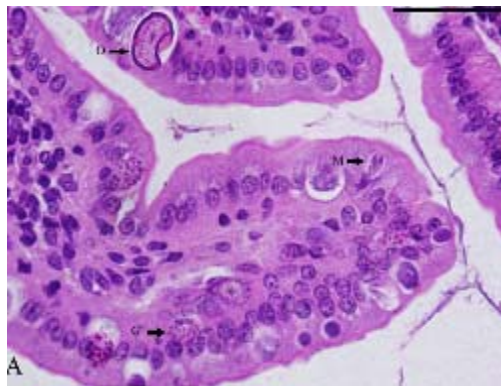


Fig. 3. Sections of mouse jejunum infected with *E. papillata* on day 5 p.i. (A) Infected jejunum showing different developmental stages appearing in the inner epithelium. (B) Infected treated mouse with fewer parasites. [M] Fully formed merozoites, [G] Gamete forming cells and [O] Developing oocysts. Sections are stained with hematoxylin and eosin. Bar=50  $\mu$ m.

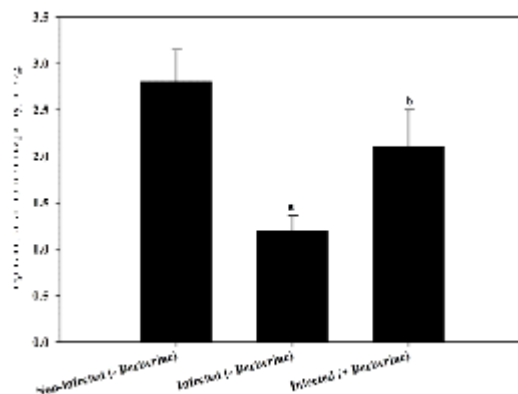


Fig 4. Changes in jejunal total antioxidant capacity in mice infected with *E. papillata* and after treatment with berberine. Values are means  $\pm$  SD. a: Significance against non-infected control group at Pd 0.05, b: Significance against infected (- Berberine) group at Pd 0.05, (n=6)

Current results showed that *E. papillata* infection induced severe disturbance in jejunal antioxidant capacity as revealed by decreasing total antioxidant capacity (TAC) from  $2.8 \pm 0.35$  to  $1.2 \pm 0.16$  mM/g (Fig 4). Upon berberine treatment of infected mice TAC within jejunum tissue was significantly reduced to be  $2.1 \pm 0.4$  mM/g (Fig 4). Coccidian parasites of the genus *Eimeria* complete their life cycles within intestinal epithelial cells and is associated with infiltration of inflammatory cells as macrophages, T-cells, neutrophils and mast cells<sup>27</sup>. This leads to initiation of cytotoxic and oxidative damage within infected mucosal tissue leading to their destruction via production of reactive oxygen and nitrogen intermediates, and

severe disturbance in the protective antioxidant systems<sup>28,29</sup>. Berberine was found to have strong antioxidant activities and inhibition of the oxidative damage in different tissues and cell lines. Chemically, it expressed a great capacity for quenching different free radicals as DPPH,  $O_2^-$ ,  $NO^-$  and  $OH^-$ <sup>30,31</sup>. Berberine also was found to activate the antioxidant enzyme systems of SOD, CAT, GST and GPX, with conservation activities of non-enzymatic antioxidant levels as GSH, Vit C and Vit E<sup>31</sup>.

Finally, it is recommended to use berberine chloride for treatment of Eimerian parasites induced coccidiosis and to enhance the intestinal antioxidant system of infected animals.



## ACKNOWLEDGEMENTS

The authors extend their appreciation to the Deanship of Scientific Research at King Saud University for funding this work through Research Group Project number RGP-198.

## REFERENCES

1. Metwaly, M.S., Dkhil, M.A., Gewik, M.M., Al-Ghamdy, A.O., Al-Quraishy, S. Induced metabolic disturbance and growth depression in rabbits infected with *Eimeria coecicola*. *Parasitol. Res.*, 2013; **112**: 3109-3114.
2. Abdel-Mageed, K.N., Abu El-Ezz, N.M., Abdel-Rahman, E.H. Protective effect of *Eimeria steidae* coproantigen against hepatic coccidiosis in rabbits. *J. Egypt. Soc. Parasitol.*, 2005; **35**: 581-595.
3. Darwish, A.I., Golemansky, V. Coccidian Parasites (Coccidia: Eimeriidae) of domestic rabbits (*Oryctolagus cuniculus* L.) in Syria. *Acta Protozool.*, 1991; **31**: 209-216.
4. Peeters, B.E., Charlier, G., Antoine, O., Mammericx, M. Clinical and pathological changes after *Eimeria intestinalis* infection in rabbits. *Zbl. Vet. Med.*, 1984; **31**: 9-24.
5. Jithendran, K.P., Bhat, K.P. Subclinical coccidiosis in Angora rabbits—a field survey in Himachal Pradesh (India). *World Rabb. Sci.*, 1996; **4**: 29-32.
6. Dkhil, M.A., Abdel-Maksoud, M.A., Al-Quraishy, S., Abdel-Baki, A.A., Wunderlich, F. Gene expression in rabbit appendices infected with *Eimeria coecicola*. *Vet. Parasitol.*, 2012; **186**: 222-22.
7. Hermosilla, C., Ruiz, A., Taubert, A. *Eimeria bovis*: An update on parasite–host cell interactions. *Int. J. Med. Microbiol.*, 2012; **302**: 210–215.
8. Turk, D.E. Protozoan parasitic infections of the chick intestine and protein digestion and absorption. *Nutr.* 1972; **102**: 1217-1222.
9. Timothy, C., Birdsall, N.D., Gregory, S., Kelly, N.D. Berberine: Therapeutic potential of an alkaloid found in several medicinal plants. *Alt. Med. Rev.*, 1997; **2**: 94-103.
10. Wongbutdee, J. Physiological Effects of Berberine. Review article. *Thai Pharm. Health. Sci. J.*, 2008; **4**: 78-83.
11. Vuddanda, P.R., Chakraborty, S., Singh, S. Berberine: a potential phytochemical with multispectrum therapeutic activities. *Expert Opin. Investig. Drugs*, 2010; **19**: 1297-1307.
12. Schito, M.L., Barta, J.R. Nonspecific Immune Responses and Mechanisms of Resistance to *Eimeria papillata* Infections in Mice. *Inf. Immun.*, 1997; **65**: 3165-3170.
13. Al-Quraishy, S., Sherif, N.E., Metwaly, M.S., Dkhil, M.A. Berberine-induced amelioration of the pathological changes in nutrient's homeostasis during murine intestinal *Eimeria papillata* infection. *Pakistan J. Zool.*, 2014; **46**: 437-445.
14. Jahnke, G.D., Price, C.J., Marr, M.C., Myers, C.B., George, J.D. Developmental Toxicity Evaluation of Berberine in Rats and Mice. *Birth Defects Res.*, 2006; (Part B) **77**: 195–206.
15. Koracevic, D., Koracevic, G., Djordjevic, V., Andrejevic, S., Cosic, V. Method for the measurement of antioxidant activity in human fluids. *Clin. Pathol.*, 2001; **54**: 356-361.
16. Kaneda, Y., Torii, M., Tanaka, T., Aikawa, M., In vitro effects of berberine sulphate on the growth and structure of *Entamoeba histolytica*, *Giardia lamblia* and *Trichomonas vaginalis*. *Ann. Trop. Med. Parasitol.*, 1991; **85**: 417-25.
17. Subbaiah, T.V., Amin, A.H. Effect of berberine sulfate on *Entamoeba histolytica*. *Nature*, 1967; **215**: 527-528.
18. Bahar, M., Deng, Y., Zhu, X., He, S., Pandharkar, T., Drew, M.E., Navarro-Vázquez, A., Anklin, C., Gil, R.R., Doskotch, R.W., Werbovetz, K.A., Kinghorn, A.D. Potent antiprotozoal activity of a novel semi-synthetic berberine derivative. *Bioorg. Med. Chem. Lett.*, 2001; **21**: 2606–2610.
19. Ghosh, A.K., Bhattacharyya, F.K., Ghosh, D.K. *Leishmania donovani*: amastigote inhibition and mode of action of berberine. *Exp. Parasitol.*, 1985; **60**: 404-13.
20. Tran, Q.L., Tezuka, Y., Ueda, J.Y., Nguyen, N.T., Maruyama, Y., Begum, K., Kim, H.S., Wataya, Y., Tran, Q.K., Kadota, S. In vitro antiplasmodial activity of antimalarial medicinal plants used in Vietnamese traditional medicine. *Ethnopharmacology*, 2003; **86**: 249-252.
21. Caraballo, A., Caraballo, B., Rodriguez-Acosta, A. Preliminary assessment of medicinal plants used as antimalarials in the Southern of Venezuelan Amazon. *Rev. Soc. Bras. Med. Trop.*, 2004; **37**: 186-188.
22. Sheng, W.D., Jiddawi, M.S., Hong, X.Q. Treatment of chloroquine-resistant malaria using pyrimethamine in combination with berberine, tetracycline or cotrimoxazole. *East Afr. Med. J.*, 1997; **74**: 283-284.
23. Sriwilaijareon, N., Petmitr, S., Mutirangura, A., Ponglikitmongkol, M., Wilairat, P. Stage specificity of *Plasmodium falciparum* telomerase and its inhibition by berberine. *Parasitol. Int.*, 2002; **51**: 99-103.

24. Serry, T.M., Bieter, R.N. A contribution of pharmacology of berberine. *Pharmacol. Exptl. Ther.*, 1940; **69**: 64-67.
25. Rosenkranz, V., Wink, M. Alkaloids Induce Programmed Cell Death in Bloodstream Forms of Trypanosomes (*Trypanosoma b. brucei*). *Molecules*, 2008; **13**: 2462-2473.
26. Krivogorsky, B., Pernat, J.A., Douglas, K.A., Czerniecki, N.J., Grundt, P. Structure-activity studies of some berberine analogs as inhibitors of *Toxoplasma gondii*. *Bioorg. Med. Chem. Lett.*, 2012; **22**: 2980-2982.
27. Laurent, F., Mancassola, R., Lacroix, S., Menezes, R., Naciri, M. Analysis of Chicken Mucosal Immune Response to *Eimeria tenella* and *Eimeria maxima* Infection by Quantitative Reverse Transcription-PCR. *Infect. Imm.*, 2001; **69**: 2527-2534.
28. Allen, P.C. Production of Free Radical Species during *Eimeria maxima* Infections in Chickens. *Poult. Sci.*, 1997; **76**: 814-821.
29. Georgieva, N.V., Koinarski, V., Gadjeva, V. Antioxidant status during the course of *Eimeria tenella* infection in broiler chickens. *Vet. J.*, 2006; **172**: 488-492.
30. Hwang, J.M., Kuo, H.C., Tseng, T.H., Liu, J.Y., Chu, C.Y. Berberine induces apoptosis through a mitochondria/caspases pathway in human hepatoma cells. *Arch. Toxicol.*, 2006; **80**: 62-73.
31. Siow, Y.L., Sarna, L., Karmin, O. Redox regulation in health and disease, Therapeutic potential of berberine, a review. *Int. Food Res.*, 2011; **44**: 2409-2417.