

Isolation and Characterization of Different Fowl Adenovirus Types Associated with Inclusion Body Hepatitis in Broiler Chickens of India

Amol Balkrushna Gulhane¹, Ashish Arunrao Deshpande¹,
Sophia Makdoh Gogoi^{2*} and Piruthivirajkumar Balaguru¹

¹Globion India Private Limited, First Floor, Plot No. 8, Devi Towers,
Chandragiri Colony, Trimulgherry, Secunderabad- 500 015, India.

²Department of Microbiology, College of Veterinary Science, Assam Agricultural University,
Khanapara, Guwahati- 781 022, India.

<https://doi.org/10.22207/JPAM.10.1.56>

(Received: 11 November 2015; accepted: 17 January 2016)

The occurrence of Inclusion Body Hepatitis in commercial broilers flocks of different parts of India was studied in order to identify the Fowl Adenovirus (FAdV) type responsible for the disease. The most common gross lesions observed during necropsy included hydropericardium, hepatomegaly, petechial haemorrhages on liver, yellowish discolouration of subcutaneous and abdominal fat along with swelling and paleness of kidneys. Histopathological examination revealed intranuclear basophilic inclusion bodies indicative of FAdV infection. Virus isolation was attempted *in-vivo*, *in-ovo* and *in-vitro* in Specific Pathogen Free (SPF) birds, SPF embryonated eggs and Chicken Embryo Liver primary cells, respectively. Antibody based detection of FAdV was suitably done with the help of Agar Gel Immunodiffusion test (AGID). Polymerase Chain Reaction and Restriction Fragment Length Polymorphism analysis was performed to detect and differentiate FAdV types. Sequencing and phylogenetic analysis revealed presence of FAdV type 2, 4, 8 and 11 in Indian poultry.

Keywords: IBH, Fowl adeno virus, broiler, PCR, characterization.

Inclusion Body Hepatitis (IBH) has emerged as a primary disease in commercial broilers. Earlier it was identified to be associated with immunosuppressive agents like Infectious Bursal Disease virus and Chicken Infectious Anaemia virus (Gomis *et al.*, 2006). Recent work has demonstrated virulent strains which alone can produce severe disease with mortality ranging from 10-30% (Dahiya *et al.*, 2002). Incidences have been reported from several countries such as India, Australia, New Zealand, England, USA, Germany, Canada, Italy, Japan and several central and South American countries (Gomis *et al.* 2006, Ojkic *et al.* 2008). IBH was first described in USA

in 1963 (Howell J. *et al.*, 1970). In Asia in 1987 it was first reported in Angara Goth near Karachi in Pakistan (Khawaja *et al.*, 1988). Gowda and Satyanarayana (1994) described the disease in birds of the age group of 3 to 6 wks characterized by sudden onset and a mortality rate as high as 75%, thereby, posing a significant threat to the poultry industry of India

The causative organism of IBH is Fowl Adenovirus (FAdV) serotype 4 belonging to group 1 FAdV of Adenoviridae family (Balamurgan and Kataria, 2004). Fowl adenoviruses (FAdV) group consist of twelve types (formerly serotypes), namely FAdV-1 to 8a, and FAdV-8b to 11 which are classified into five different species (A-E) (Zdravec *et al.* 2013). FAdVs are non-enveloped, 70-80 nm in diameter single linear double stranded DNA (dsDNA) with icosahedral structure,

* To whom all correspondence should be addressed.
Mob.: +91-9706072570 ;
E-mail: sophiagogoi@gmail.com

composed of 252 capsomers. Out of these 252 capsomers, there are 12 vertex capsomers (penton bases) and 240 non-vertex capsomers (hexons). There are seven polypeptides present in virion capsid. Hexon, as a major protein of the adenovirus capsid, is known to have region related to virus neutralizing and serotype specificity (Toogood *et al.* 1989).

The current study was undertaken to investigate IBH affecting commercial broilers flocks in India. The study aims to isolate and characterize the FAdV types involved in the disease and thus provide actual data pertaining to the disease scenario.

MATERIALS AND METHODS

Sample collection

Liver samples were collected from IBH suspected broiler birds from different parts of India. For virus isolation livers were collected in Phosphate buffer Saline (GPBS) contained in sterile containers and brought to the laboratory maintaining cold chain. For histopathological investigations similar liver tissues were collected in 10% buffered formalin and submitted to VBRI Shanthinagar Hyderabad, India.

Preparation of samples

20% W/V suspension of collected liver tissues were prepared in sterile PBS and centrifuged at 3000g for 15 minutes at 4°C. The supernatants were filtered using 0.22 micron syringe filters and were stored at -20°C for virus isolation and molecular confirmation.

Virus Isolation

Infection of Specific Pathogen Free (SPF) birds

For *in vivo* isolation, the liver suspension was inoculated into 3 wks old SPF birds by intramuscular route at the dose rate of 0.5 ml per bird and observed for 144 hours. The dead birds were examined for lesions and livers were collected for histopathological and molecular studies.

Infection in SPF eggs

Isolation was also attempted in 10 day old embryonated SPF eggs by inoculating the 20% liver suspension into the eggs by allantoic route at the rate of 0.1ml per egg. The eggs were incubated for 144 hrs post inoculation (hpi). Daily inoculated eggs were observed by candling and all dead embryos were examined for changes in

the viscera. Liver samples were also collected for histopathological and molecular study.

Infection of Chicken Embryo Liver (CEL) cells

CEL cells were prepared from 14 day old SPF embryos following the procedure of Penelope A. Steer and Amir H. Noormohammadi (2011) with few modifications. 25 cm² culture flasks (Corning) were seeded with 0.5 x 10⁶ cells per cm² using Medium 199 (Himedia) containing 10% Fetal Bovine Serum (FBS) (Sigma) in a total volume of 10 ml and incubated at 37°C with 5% CO₂. Medium was changed every 24 to 48 hrs, until the cell monolayer became confluent (approximately 60-72 hrs). For infecting the cells, the medium was discarded and the confluent CEL monolayer was inoculated with 100 µl of the 20% liver suspension and 400 µl of maintenance medium containing 2% FBS. Following an incubation period of 1 hour, maintenance medium was added to increase the volume up to 10 ml. The cells were further incubated until cytopathic effect (CPE) was observed in more than 80 percent of the cells. The virus thus propagated in the cells was harvested by freezing (-70°C) and thawing the culture thrice followed by centrifugation at 1500g for 10 min to separate cell debris. The supernatant was collected and stored in aliquots at -70°C for further molecular and serological studies.

Identification of the virus

Agarose gel immune diffusion (AGID) test

AGID was performed as per the procedure described in OIE manual (2013) for Infectious Bursal Disease with minor modifications for detection of FAdV antigen in suspected samples. Hyperimmune serum was raised in five, 2-weeks-old SPF birds by inoculating 0.5 ml of Inactivated IBH vaccine- FAdV Type 4 (Globion India Pvt Ltd) by intramuscular route, booster injections with the same dose were given weekly upto 5 weeks of age. The blood samples were collected 14 days post-final booster. Sera were separated, heat inactivated at 56°C for 30 minutes and stored at -20°C until further use.

1% Agarose (Agarose medium EEO) was prepared in a buffer solution containing sodium chloride -8.0 g, kalium dihydrogenophosphate -0.45 g, sodium hydrogenophosphate dihydrate -1.19 g and distilled water to a final volume of 1 litre (final P^H 7.1 at 20–25°C). 5 ml dissolved agarose was poured into 30mm plastic Petri dishes

placed on a level surface. Covered plates were allowed to set at 4°C overnight and later kept at 37°C in an inverted position for 30 minutes before proceeding with the test. Wells of 3 mm diameter were cut 3 mm apart by using a template and tubular cutter. The bottom of the wells were sealed with molten agarose. The central well was loaded with 20 µl hyperimmune sera and the surrounding wells with 20 µl each of the suspected samples. The plates were incubated for 24-36 hrs in a moist chamber at 37°C and observed for presence of precipitation lines.

Polymerase Chain Reaction (PCR)

Hexon protein gene of fowl adenovirus group-I was chosen (Meulemans *et al.*, 2001) for this study. Viral DNA was extracted from the liver suspensions and CEL propagated cell culture fluid by Trizol LS (Life science) method as per the manufacturer's protocol. The purity and quantity of extracted DNA was checked by using Nanodrop (Thermo).

DNA amplifications were carried out in a total volume of 25 µl containing 100-150 nano gram viral DNA, 1 µMol each primer and 1 U Taq DNA polymerase (Thermo) using the following conditions: denaturation- 94°C, 30 Sec; annealing- 48°C, 1 min; extension-72°C, 1 minute; 30 cycles followed by a final extension step- 72°C, 8 min. The amplified products were analyzed by electrophoresis in a 1.8% agarose gel, stained with ethidium bromide and visualized by UV transillumination.

Restriction analysis

8 µl of unpurified PCR product was incubated with 5 U of restriction enzyme BsiWI (New England Biolabs) at 55 °C for 1 hour. Products obtained by restriction enzyme digestion were separated electrophoretically on a 2% agarose gel, stained with ethidium bromide and visualized by UV transillumination.

DNA sequencing and phylogenetic analysis

The positive PCR products along with the primers were submitted for DNA sequencing. Consensus sequence thus obtained were aligned

with various published sequences of the Hexon protein gene in Genbank using NCBI Blast. All the nucleotide sequences were aligned for phylogenetic analysis using the CLUSTAL OMEGA software programme.

RESULTS

Gross and histopathology

Necropsy of the affected birds revealed prominent changes which included hydropericardium, accumulation of jelly fluid in the pericardial sac (Fig. 1 A), marked hepatomegaly with haemorrhages, splenomegaly and nephritis. However, the picture was different in certain birds in which yellowish discoloration of the subcutaneous and abdominal fat, swollen and pale kidneys (Fig. 1 B), enlarged liver with petechial haemorrhages (Fig. 1 C) were observed without any evidence of hydropericardium.

H&E staining of formalin fixed liver tissue sections revealed intranuclear basophilic inclusion bodies indicative of FAdV infection (Fig. 2).

Virus isolation

Virus isolation and disease reproduction trial was done in 3 week old SPF birds. 20-80 % mortality was observed within 144 hpi. The remaining birds showing illness later recovered. Necropsy of dead birds revealed similar lesions as mentioned earlier prominently, confirming the reproducibility of the disease. The SPF eggs inoculated with the liver suspension remained alive for 144 hpi. These embryos showed marked hepatomegaly with yellow pigmentation and haemorrhages on liver.

The propagation of the virus in the CEL cells was evident by the observance of cytopathic effect like rounding of cells in 60-72 hpi. and detachment of cells by 96 hrs. 72 hrs post infection, 80% of the cells became rounded (Fig. 3). Histopathology and PCR analysis substantiated the presence of the virus in the experimentally infected chicks, embryos and CEL cells.

Table 1. Restriction fragment length polymorphism band sizes for Hexon gene digested using BsiWI

FAdv species	Type 2 (Group D)	Type 4 (Group C)	Type 8 (Group E)	Type 11 (Group D)
Band Sizes	680 and 217 bp	897 bp (n.c.*)	897 bp (n.c.*)	897 bp (n.c.*)

*n.c. Not cut

Agarose gel immune diffusion (AGID) Test

The liver suspensions and CEL propagated cell culture fluid were tested by AGID employing the hyperimmune sera raised with the FAdV Type 4 vaccine. A line of precipitation was observed in 3 of the samples (Fig. 4) indicating FAdV type 4 infection.

PCR and RFLP analysis

Hexon gene of fowl adenovirus was amplified from viral DNA to obtain 897 bp PCR product which was resolved on 1.8% agarose gel (Fig.5). Out of 48 samples collected from the different poultry farms, 24 were found to be positive by PCR. Mentionably, corresponding samples showed positive changes in SPF chicks, embryonated eggs and CEL cells. The samples found to be negative by PCR could not be propagated in the SPF chicks, embryos and CEL cells. Digestion of 897 bp PCR products using BsiW1 restriction endonuclease revealed distinct restriction patterns (Fig. 6), the details of which are included in Table 1.

Sequence analysis

Sequence analysis of Fowl adenovirus hexon gene with Blast programme (NCBI) revealed identity with FAdV 2 (1 samples), FAdV 4 (3 samples), FAdV 8 (1 samples) and FAdV 11 (19 samples). Sequences were also submitted to Genebank (NCBI) (Table 2). Phylogenetic analysis of these sequences with FAdV genebank sequences using Clustal W2 program (Fig. 7) revealed different clusters of FAdV (group D, E and C).

DISCUSSION

The gross pathological changes recorded during this investigation are comparable to the descriptions made by Gowda and Satyanarayana (1994), Shane (2000), Chandra *et al* (2000) and

Table 2. Genebank Accession no. of FAdV isolates submitted to NCBI

S. No.	Genebank Accession No.	Laboratory identity of FAdV Isolates
1	KR023952	2008 P4
2	KR152221	238 D
3	KR338963	411-13 A1
4	KR363152	460-13
5	KR559772	398-14 C
6	KR559773	402-14 A
7	KR559775	411-13 A2
8	KR559776	411-13 B2
9	KR559777	416-13 A
10	KR559778	430-14
11	KR559779	439-14 C
12	KR559780	484-14
13	KR559781	489-14 A
14	KR559782	496-14 A
15	KR781101	508-14 A
16	KR781102	509-14 A
17	KR781103	510-13
18	KR781104	510-14 D
19	KR781105	514-14 C
20	KR781106	514-14 E
21	KR781107	516-14 A
22	KR781108	544-13
23	KR781109	650-13 A3
24	KR781110	675-13 A

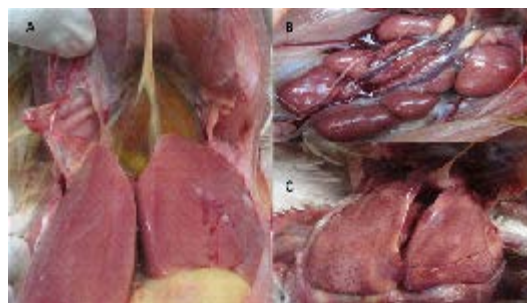

Fig 1. Gross lesions of IBH affected chickens. A) hydropericardium, accumulation of jelly fluid in pericardial sac, marked hepatomegaly with haemorrhages. B) Swollen and pale kidneys. C) Swollen liver with diffused haemorrhagic and necrotizing foci

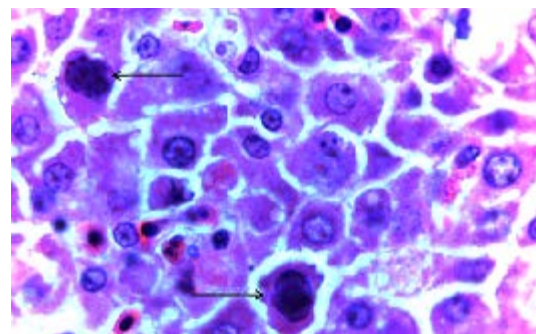


Fig. 2: Hepatocytes with large basophilic intranuclear inclusion bodies (arrows) (1000×)

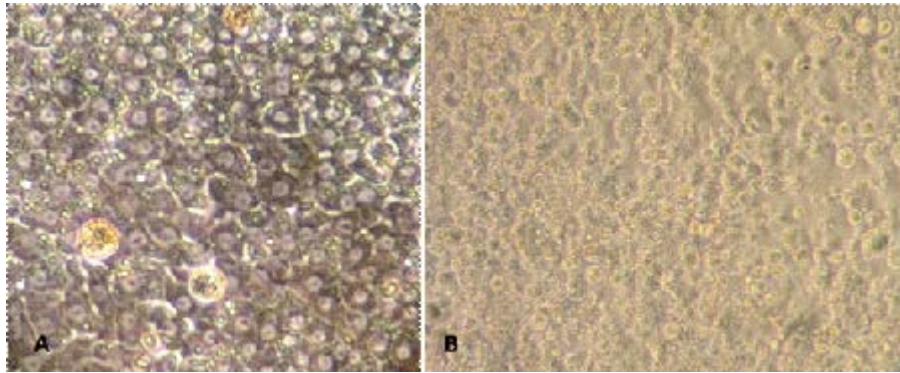


Fig. 3. Cytopathic effect of FAdV in CEL cells. A) Eighty percent confluent CEL cells. B) Typical cytopathic effects of cell rounding, refractility and detachment of cells at 72 hrs. post inoculation of FAdV

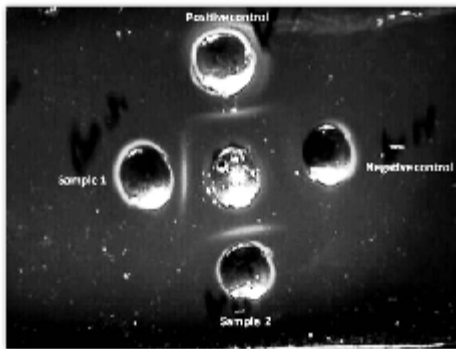


Fig 4: Agarose-gel immunodiffusion of chicken liver suspension and CEL harvest using FAdV 4 hyperimmune sera (central well). Peripheral wells contain FAdV 4 liver suspension (positive control), liver suspension (Sample 1) and CEL harvest (Sample 2)

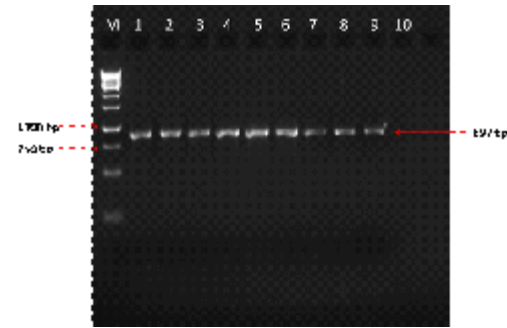


Fig 5: Agarose gel (1.8%) electrophoresis showing amplified PCR product (897 bp) of field isolates. Lane M: 1kb ladder; Lane 1-8: PCR product of field isolates; Lane 9: Positive control; Lane 10: Negative Control

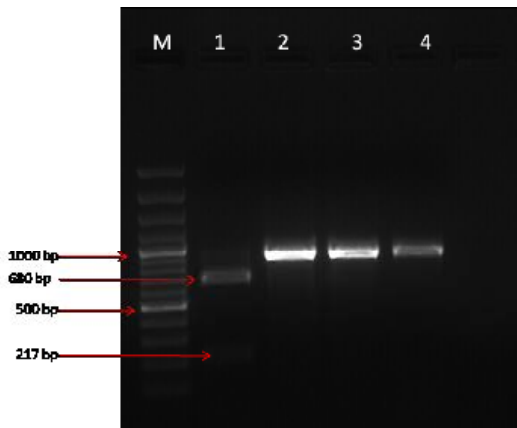


Fig 6. Restriction endonuclease analysis of the PCR amplified hexon gene from representative four types of FAdV digested with BsiW1. Lane M: 100 bp ladder; Lane 1: FAdV type 2; Lane 2: FAdV type 4; Lane 3: FAdV type 8; Lane 4: FAdV type 11

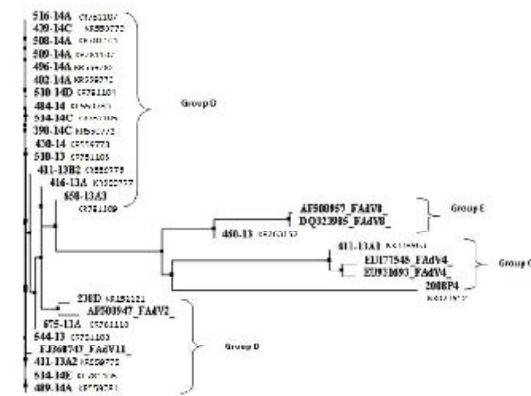


Fig. 7. Phylogenetic tree based on nucleotide sequence of hexon gene of FAdV field isolates and sequences from Gene bank

Amit Gaba *et al.* (2010). In few cases, it was also found that hydropericardium was not apparent. Similar findings were earlier reported by Grimes *et al.* (1977), Cook (1983) and Reece *et al.* (1986). The histopathological changes observed in the liver samples were in accordance with the changes described by Gowda and Satyanarayana (1994), Shane (2000), Chandra *et al.* (2000) and Amit Gaba *et al.* (2010) for FAdV diagnosis.

In the present study, the virus could be successfully propagated in the SPF chicks and embryos. Samantha Eknayake (2009) also discussed a similar pathogenesis pattern of FAdV in SPF chicks. The infected embryos exhibited changes comparable to those seen in IBH infected chicks. Moreover, the virus could be suitably adapted to grow in the CEL cells as was evident from the consistent CPE observed in all the positive samples. Similar changes were reported by Samantha Eknayake (2009) and Kumar *et al.* (2010).

As per the findings of our study, PCR analysis provided accurate detection of FAdV in both liver samples and cell culture fluid. The same set of primers developed by Meulemans *et al.* (2001) were also employed by K.B. Thakor *et al.* (2012), Amit Gaba *et al.* (2010) and Dahiya *et al.* (2002) for detection of FAdV. Furthermore, restriction patterns with BSiW1 enzyme observed in the present study were in accordance with the RFLP analysis reports of Meulemans *et al.* (2001) excluding FAdV type 11 which showed no digestion with BSiw1 enzyme. Pattern obtained with FAdV 11 may have appeared due to point mutation at the cut site of enzyme. PCR products showing different restriction patterns were confirmed by sequencing for identification of fowl adenovirus types. Also AGID test was found to be useful for detection of the viral antigen. Although the test lacks high sensitivity, it is relatively simple to perform and can provide preliminary diagnosis.

The present study accounts the occurrence of FAdV types 2, 4, 8 and 11 in Indian Poultry. Previously, isolation of FAdV type 4 and FAdV type 11 from outbreaks of IBH in India have been reported (Dahiya *et al.*, 2002, Amit Gaba *et al.*, 2010 and K.B Thakor *et al.*, 2012). Shamim *et al.* (2009) also documented the association FAdV type 4 with HPS in Pakistan.

IBH has been primarily believed to be

associated with FAdV type 4 but the findings of our study present a different picture of the progression of the disease. Accurate diagnosis of the disease is, therefore, of utmost importance. In our study, different methods were utilized for isolation and identification of the causative agent to assess their suitability in providing conclusive results. Evidence of involvement of different serotypes of FAdV in the production of IBH necessitates extensive studies for better comprehension of the pathogenicity of the above FAdV types either alone or in synergy. It also raises the possibility of development of improved vaccines which can confer protection against multiple types of FAdV. In a nutshell, disease control strategies have to be reassessed to reverse the emergence of IBH as a major threat to the Indian poultry industry.

REFERENCES

1. Amit Gaba, Hitesh Parmar, J.K.Pal and K.S.Prajapati. Isolation, identification and molecular characterization of Inclusion body hepatitis virus, *Veterinary World*, 2010; **3**(9) 415-417
2. Balamurgan V and Kataria J.M. The Hydropericardium Syndrome in Poultry- A current Scenario *Vet. Res. Comm.*, 2004; **28** : 127-148
3. Chandra R., S.K. Shukla and M. Kumar. The hydropericardium syndrome and inclusion body hepatitis in domestic fowl. *Tropical Animal Health and Production*. 2000; 32:99-111
4. Cook, J. K. A. Fowl adenoviruses: Studies on aspects of the pathogenicity of six strains for 1-day-old chicks. *Avian Pathol.*, 1983; **12**(1): 35-43
5. Dahiya S., R.N. Srivastava, M. Hess and B.R. Gulati. Fowl adenovirus serotype 4 associated with outbreaks of infectious hydropericardium in Haryana, *Avian Dis.*, 2002; 46:230-233.
6. Gomis, S., Goodhope, R., Ojkic, D., and Willson, P. Inclusion body hepatitis as a primary disease in broilers in Saskatchewan, Canada. *Avian Dis.*, 2006; **50**(4): 550-555
7. Gowda, R.N.S. and M.L. Satyanarayana. Hydropericardium syndrome in poultry. *Ind.J. Vet. Path.*, 1994; 18:159-161.
8. Grimes, T. M., and King, D. J. Serotyping avian adenoviruses by a microneutralization procedure. *Am. J. Vet. Res.* 1977; **38**(3): 317-321
9. Howell J, MacDonald D. W. and Christian R.J. Inclusion body Hepatitis In Chickens, *Can. Vet.*

- J.*, 1970; 11: 99-101
10. KB Thakor, CJ Dave, KS Prajapati, DT Fefar and BM Jivani. Molecular characterization of Avian Adeno virus causing Inclusion Body Hepatitis-Hydropericardium syndrome in broiler chickens of Anand, Gujarat, India. *Vet. World.* 2012; **5(3)** 178-182.
 11. Khawaja, D.A., S. Ahmed, M.A. Raeuf, M.Z. Zulfiqar, S.M.I. Mahmood and M. Hasan,. Isolation of an adenovirus from hydro pericardium syndrome in broiler chicks, *Pak. J. Vet. Res.*, 1988; 1: 2-17
 12. Kumar R, Kumar V, Asthana M, Shukla SK and Chandra R. Isolation and identification of Fowl adenovirus from Wild Black Kites (*Milvus migrans*). *J. Wild Dis.* 2010; 46(1): 272-276.
 13. Meulemans G., M. Boschmans , T. P. van den Berg and M. Decaesstecker. Polymerase chain reaction combined with restriction enzyme analysis for detection and differentiation of fowl adenoviruses, *Avian Pathology.* 2001; **30**, 655–660
 14. Office International Des Epizootics (OIE) 2013; Manual of Diagnostic Tests and Vaccines for Terrestrial Animals.
 15. Ojkic, D., Krell, P. J., Tuboly, T., and Nagy, É. Characterization of fowl adenoviruses isolated in Ontario and Quebec, Canada. *Can. J. Vet. Res.* 2008; **72(3)**: 236-241
 16. Penelope A. Steer and Amir H. Noormohammadi. Inclusion Body Hepatitis Outbreaks in Australian Meat Breeder and Broiler Flocks. In: RIRDC Publication No. 11/034, RIRDC Project No. PRJ-000610. 2011; <https://rirdc.infoservices.com.au/downloads/11-034>
 17. Reece, R. L., Barr, D. A., Grix, D. C., Forsyth, W. M., Condron, R. J., and Huindmarsh, M. Observations on naturally occurring inclusion body hepatitis in Victorian chickens. *Aust. Vet. J.* 1986; **63(6)**: 201-202
 18. Samantha Eknayake. Inclusion Body Hepatitis as a primary disease in commercial broiler chickens.,M.Sc thesis . 2009; University of Saskatchewan, Canada .
 19. Shamim,S., S.F. Rehmani, A.A. Siddiqi, M.A. Qureshi and T.A. Khan. Characterization of avianadenovirus type-4 causing hydropericardium syndrome in broilers in Karachi, Pakistan. *Iranian Journal of Veterinary Research.* 2009; 1:38-43.
 20. Shane, S. Hydropericardium hepatitis update. *Poult. Intl.*, 2000;39:52-54.
 21. Toogood, C.I.A., M urali, R., Burnett, R.M. and Hay, R.T., The adenovirus type 40 hexon: sequence, predicted structure and relationship to other adenovirus hexons. *J. Gen. Virol.* 1989; **70**: 3203-3214.
 22. Zadavec, M., B. Slavec, U. Krapež, G.L. Kaján, J. Raènik, P. Juntos, R. Juršič Cizerl, M. Benkō and O.Z. Rojs. Inclusion body hepatitis (IBH) outbreak associated with fowl adenovirus Type 8b in broilers. *Acta Veterinaria (Beograd).* 2013; **63(1)**: 101-110

© The Author(s) 2016. Open Access. This article is distributed under the terms of the [Creative Commons Attribution 4.0 International License](https://creativecommons.org/licenses/by/4.0/) which permits unrestricted use, sharing, distribution, and reproduction in any medium, provided you give appropriate credit to the original author(s) and the source, provide a link to the Creative Commons license, and indicate if changes were made.